

Retinopathy of prematurity (ROP) is a vaso-proliferative disorder of the retina among preterm infants. Neonates born at less than 32 weeks of gestation are at risk of developing ROP. However preterm infants born at 32 weeks or later can also develop severe ROP if they had turbulent NICU course or required prolonged oxygen therapy. Nearly one-fourth of neonates undergoing screening may show some degree of ROP which fortunately regresses on its own in majority of affected infants, in a few it progresses to the stage of retinal detachment and blindness. Timely screening and treatment of ROP can prevent blindness and minimize visual handicaps.

What is evidence?

Studies from India have reported ROP in 20% to 52% of screened neonates.¹⁻⁹ More recent studies reporting lower rates of ROP ranging from 20% to 30%.^{1,2}

Classification of ROP

International Classification of ROP (ICROP) is used for classifying ROP.¹⁰ ICROP describes vascularization of the retina and characterizes ROP by its position (zone), severity (stage), and extent (clock hours) (Figure 37.1 and Table 37.1).

Aggressive posterior ROP (AP-ROP): A rapidly progressing, severe form of ROP, if untreated, usually progresses rapidly to stage 5 ROP. The characteristic features of this type of ROP include its posterior location, prominence of plus disease, and the ill-defined nature of the retinopathy. This may not have classical ridge or extraretinal fibrovascular proliferation, but rather have innocuous looking retina and tortuous vessels forming arcades. This type of ROP is likely to get missed by inexperienced examiners. Observed most commonly in Zone I, it may also occur in posterior Zone II.

Table 37.1: Classification of ROP (ICROP)¹⁰

Location	Zone 1	Circle with optic nerve at its centre and a radius of twice the distance from optic nerve to macula
	Zone 2	Concentric circle from edge of zone 1 to ora serrata nasally and equator temporally
	Zone 3	Lateral crescent from zone 2 to ora serrata temporally
Severity	Stage 1	Presence of thin white demarcation line separating vascular from avascular retina
	Stage 2	Addition of depth and width to the demarcation line of stage 1, so as the line becomes ridge
	Stage 3	Presence of extra retinal fibrovascular proliferation with abnormal vessels and fibrous tissue extending from ridge to vitreous
	Stage 4	Partial retinal detachment not involving macula (4A) and involving macula (4B)
	Stage 5	Complete retinal detachment
Plus disease		Presence of dilatation and tortuosity of retinal vessels at posterior pole of eye. Also associated with papillary rigidity and vitreous haze.
Extent		Extent of ROP described in 30 ^o clock hours (a total of 12 clock hours of 30 ^o each)

Name: _____ Birth weight: _____ Gestation at birth: _____ week Date of screening: _____

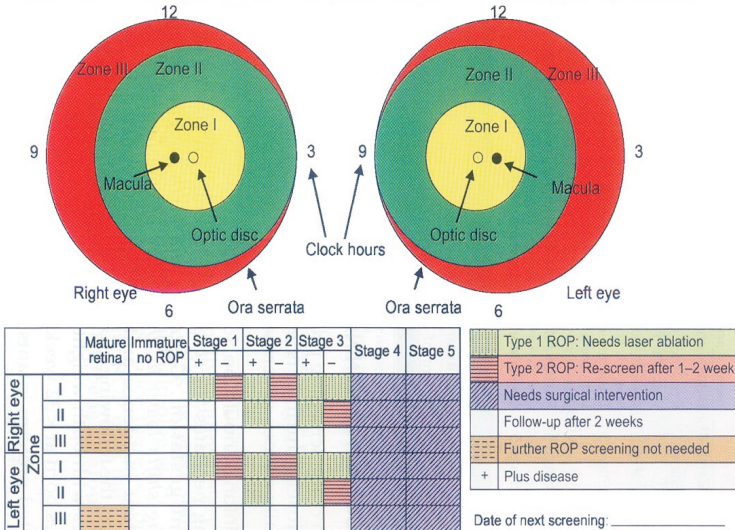


Figure 37.1: Classification of retinopathy of prematurity

Protocol for screening

The aim of the screening program is to detect ROP early, follow it up closely during its evolution, and treat if it assumes potentially serious severity level.

Which infants should be screened?

Selecting neonates for screening depends on risk of ROP at different gestation. Gestation and birth weight cut-off for screening shifts lower as the units gain expertise in managing preterm babies and improve the quality of care that they provide. Therefore, screening criteria may vary in different neonatal units. Units (arbitrarily classified as category 1) which have an established ROP screening program and have documented no case of ROP needing treatment among neonates born at more than 32 weeks of gestation over last 2-3 years may shift to stricter criteria for screening.² Units (category 2 units) which have no or recently established ROP screening program, have documented instances of ROP needing treatment among neonates born at more than 31 weeks of gestation or admit outborn neonates with unclear history of oxygen exposure should follow more liberal criteria for screening.^{7,11} (Table 37.2)

When and how often to screen

First screening examination should be carried out at 32 weeks of post menstrual age (PMA) or 4 weeks of postnatal age (PNA), whichever is later.¹² For infants less than 28 wk, screen at 3 wk of postnatal age to detect APROP.

Practice tip

A good rule to remember is to perform first screening at 4 weeks of PNA.

What is evidence?

Progression of ROP follows a distinct timeline as per PMA rather than postnatal age (PNA) of the infant. Hardly any ROP is detected before 32 weeks of PMA. However, ROP usually does not develop before 3 weeks of PNA.

The median age at detection of stage 1 ROP is 34 weeks. Threshold ROP appears at 34 to 38 weeks. Vascularization is complete by 44 weeks of gestation. Therefore, critical phase during screening is 34 to

38 weeks when the infant is likely to reach the threshold stage of disease and may require treatment for prevention of blindness.

Table 37.2: ROP screening criteria

Criteria for screening	Category 1 neonatal units	Category 2 neonatal units
Gestation and birth weight cut-off	Gestation less than 32 weeks or birth weight <1500 g	
Additional criteria	Gestation 32-34 weeks or if reliable gestation at birth not known birth weight 1501-2000g AND Any of the following: <ul style="list-style-type: none"> • CPAP or ventilation for any duration • Oxygen therapy for 24 h or more • Inotropic support • Anemia needing blood transfusion • Culture positive sepsis 	<ul style="list-style-type: none"> • Gestation 32-34 weeks or if reliable gestation at birth not known birth weight 1501-2000 g AND Admitted in neonatal unit for any reason • Gestation 35-36 weeks AND Any of the following: <ul style="list-style-type: none"> • CPAP or ventilation for any duration • Oxygen therapy for 24 h or more • Inotropic support • Anemia needing blood transfusion • Culture positive sepsis

In addition to prematurity, other risk factors of developing ROP include anemia, blood transfusion, sepsis, apnea, hypotension and poor weight gain. In general, other risk factors are surrogate markers of sickness in the baby. Therefore, sicker the baby higher is the risk.³

Follow-up examinations are normally required every 1-2 weeks depending upon ROP staging, and should be recommended by the examining ophthalmologist.

ROP screening can be terminated once there is complete vascularization of retina without any ROP, or if the ROP has shown regression. This normally happens at around 40 to 44 weeks of PMA.

Where to examine the baby?

Neonates are best examined in the neonatal unit itself under

supervision of attending pediatrician/neonatologist. It is not wise to transport small babies to ophthalmic outpatient or ward for examination.

How to dilate the pupils?

Pupils are dilated with phenylephrine 2.5% and tropicamide 0.5% to 1%. One drop of tropicamide is instilled every 10-15 minutes up to 4 times starting 1 hour before the scheduled time for examination. This is followed by phenylephrine, just one drop before examination. Phenylephrine is available in 10% concentration; it should be diluted 4 times before use in neonates. Repeated instillation of phenylephrine is avoided for the fear of hypertension.

Practice tip

If pupils are not dilating despite administration of adequate mydriatic drops, aggressive-posterior ROP should be suspected.

What does the examination entail?

Screening of ROP involves indirect ophthalmoscopy (IO) using 20D or 28/30 D lens by an experienced ophthalmologist. After instilling a topical anesthetic drop like proparacaine, a wire speculum is inserted to keep the eye-lids apart. First the anterior segment of the eye is examined to look for tunica vasculosa lentis, pupillary dilation, and lens / media clarity followed by the posterior pole to look for plus disease, followed by sequential examination of all clock hours of the peripheral retina. A sclera depressor is often used to indent the eye externally to examine areas of interest, rotate and stabilize the eye.

How to record findings during screening?

Ophthalmological notes should be made after each ROP examination, detailing zone, stage and extent in terms of clock hours of any ROP and the presence of any pre-plus or plus disease. These notes should include a recommendation for the timing of the next examination (if any) and be kept with the baby's medical record (Figure 35.1 in Appendix).

What precautions are taken during examination?

ROP screening examination can have short-term effects on blood pressure, heart rate and respiratory function in the premature baby.¹³ The examination should be kept as brief as possible and precaution is taken to ensure that emergency situations can be dealt with promptly and effectively. Discomfort to the baby should be minimized by administering oral sucrose just before examination, pretreatment of the eyes with a topical proparacaine and swaddling the baby. Baby should not be fed just before examination to avoid vomiting and aspiration. Hand hygiene should be practiced to maintain asepsis.

What is evidence?

A systematic review and meta-analysis comprising four studies has reported that oral sucrose reduces pain during eye examination.^{13,14} Of two studies reporting the role of topical proparacaine drops, one observed significant pain reduction.¹⁵

Use of wide-field digital camera (RetCam) for screening

Wide-field digital cameras capable of retinal imaging have been evaluated as an alternative to IO for screening in preterm infants. Retinal images taken by camera can be stored, transmitted to expert, reviewed, analyzed and sequentially compared over time and are useful for telemedicine purposes. However, due to high cost and variable sensitivity, wide-field digital cameras have not been used widely as replacement for IO.¹⁶ Various low-cost alternatives are under development and are likely to be available over next few years. However, efficacy of these cameras is dependent not only on technical capabilities but also on the expertise and supervision of healthcare worker obtaining the retinal image, mechanism in place for timely review of images and ability to provide treatment when severe ROP is detected. A program with all these components needs to be validated before new generation wide-angle cameras are put into use.

What is evidence?

Studies comparing Retcam with indirect ophthalmoscopy (IO) have reported variable sensitivity but good specificity.¹⁶

Treatment

The treatment involves ablation of peripheral normal avascular retina and thereby abolishing hypoxic drive of retina (mediated by over-expression of vascular endothelial growth factor; VEGF). This results in regression of established ROP. Care is taken not to touch the retina with ROP as it would result in severe bleeding.

Indication for peripheral retinal ablation

Treatment of ROP is based on differentiation of following two types of ROP:

Type 1 ROP

- Zone I, any stage ROP with plus disease
- Zone I, stage 3 ROP without plus disease
- Zone II, stage 2 or 3 ROP with plus disease

Type 2 ROP

- Zone I, stage 1 or 2 ROP without plus disease
- Zone II, stage 3 ROP without plus disease

Peripheral retinal ablation should be carried out for all cases with type 1 ROP and continued serial examinations are advised for type 2 ROP.

What is evidence?

Classification of ROP into type 1 and 2 is based on results of Early Treatment for Retinopathy of Prematurity Randomized Trial (ETROP).¹⁷ Before ETROP study laser ablation was performed in neonates with threshold ROP, a classification based on location and stage of ROP.

ETROP study demonstrated improved visual outcome if laser ablation is performed in eyes with 'high-risk' pre-threshold ROP. Type 1 ROP includes threshold ROP and subset of pre-threshold ROP likely to benefit from early treatment.

Treatment modalities

Peripheral retinal ablation is carried out either by cryotherapy or by diode laser. Diode laser ablation has largely replaced cryotherapy as it is associated with a lower rate of postoperative ocular and systemic complications and lesser damage to the adjacent tissues. Additionally, 'laser spots' on retina are visible during the procedure minimizing the skip areas requiring re-treatment. The procedure can be carried out under general anesthesia or under sedation depending on the feasibility and expertise.

What is evidence?

In a Cochrane systematic review peripheral retinal ablation as compared to no treatment was associated with improved structural and functional outcome in treated eyes.¹⁸ Due to ablation of peripheral avascular retina, visual fields were reduced in treated eyes.

Pre-anesthetic preparation

Oral feeds should be discontinued 3 hours prior to the procedure (Table 37.3). Baby should be started on intravenous fluids, and put on cardio-respiratory monitor. Dilatation of pupil is ensured (as described earlier).

Anesthesia/sedation

Topical anesthesia alone provides insufficient analgesia for ROP treatment and should not be solely relied upon. Ideally, babies should be treated under general anesthesia or under opioid sedation in an operation theatre. If shifting to operation theatre is not possible or is causing delay in treatment, babies may be treated more rapidly in the neonatal unit under adequate sedation and analgesia.

Procedure

Both the eyes can be treated at the same sitting unless contraindicated by instability of the baby. If baby is not tolerating the procedure, consider abandoning the procedure for the time being. Vital signs and oxygen saturation should be monitored very closely.

Monitoring after laser therapy

After laser therapy first examination should take place 5-7 days after treatment and should be continued at least weekly for signs of decreasing activity and regression. Re-treatment should be performed usually 1 to 4 days after initial treatment when there has been a failure of the ROP to regress.

Post-operative care

- The baby should be closely monitored. If condition permits, oral feeds can be started shortly after the procedure.
- Premature babies, especially those with chronic lung disease may have increase or re-appearance of apneic episodes or an increase in oxygen requirement. Therefore, they should be carefully monitored for 48-72 hours after the procedure.
- Antibiotic drops (such as chloramphenicol) should be instilled 6-8 hourly for 2-3 days.

Bevacizumab

Intravitreal injection of bevacizumab, a neutralizing anti-VEGF molecule has been demonstrated to diminish the neovascular response significantly in animal models and human studies. As VEGF is an important mediator of lung growth and brain development, and there is significant systemic absorption of anti VEGF medication after intravitreal injection, there are concerns regarding toxicity of such therapy. Due to lack of data on potentially serious systemic adverse effects, administration of intravitreal bevacizumab (anti-VEGF monoclonal antibody) is not routinely recommended in neonates with ROP.¹⁹ It may be used only when laser photocoagulation fails and after taking informed consent from the parents.

What is evidence?

A multicentre RCT showed that intravitreal injection of bevacizumab is superior to conventional laser therapy in infants with treatable ROP (stage 3+) in zone I but not in zone II.²⁰ Additional advantage of bevacizumab was that retinal vessels continued to grow as opposed to permanent destruction of the same with laser therapy.^{21,22} The trial was not large enough to rule out potential serious side effects of this treatment modality. A meta-analysis

published in 2018 suggests that intravitreal anti VEGF reduces the risk of refractive errors during childhood but not retinal detachment.

Table 37.3: Preparation for laser ablative therapy

- Take consent
- Ensure good pupillary dilatation
- Nil by mouth 3 h prior to procedure
- Start on intravenous fluids
- Put on vital sign monitor/ pulse oximeter
- Warmer for maintaining temperature
- Arrange equipment and check functioning thereof
 - o Endotracheal tubes No. 2.5, 3, 3.5
 - o Resuscitation bag & face masks
 - o Oxygen delivery system
 - o Syringes, infusion pumps, ventilator

Prevention

Antenatal steroids

Use of prenatal steroids is a well-known approach to prevent respiratory distress and intraventricular hemorrhage, two important risk factors of ROP. Though antenatal steroids have not reduced occurrence of ROP, perhaps because it saves smaller babies who are at higher risk of developing ROP, but, as it reduces sickness level in preterm infants, prenatal steroids are likely to reduce severe ROP.

Judicious oxygen therapy

Oxygen is a drug and it should be used judiciously. Each neonatal unit should have a written policy regarding when and how to use oxygen and target saturations.

If a preterm neonate <32 weeks gestation needs resuscitation at birth, inhaled oxygen concentration (FiO_2) should be titrated to prevent hyperoxia and achieve gradual increase in oxygen saturation (70% at 3 minute and 80% at 5 minute after birth).²³ During acute care of a sick preterm neonate, ROP is more likely to develop if partial pressure of oxygen in arterial blood is more than 80 mm Hg.

Oxygen level in blood should be continuously monitored using pulse oximetry keeping a saturation target of 90% to 93%, with limits set at 88% and 95%. It is important that a work culture is inculcated wherein physicians and nurses respond to monitor alarms.

What is evidence?

A large scale RCT (SUPPORT trial) indicated that maintaining low saturations (85% to 89%) compared to high saturations (91% to 95%) in preterm infants <28 week did not reduce composite outcome of death or severe ROP but it resulted in lower severe ROP and higher death rates.²⁴

Therefore it is recommended that saturations in preterm neonates be maintained between 90% and 95%. Saturations should be monitored in preterm infants receiving oxygen therapy to prevent hyperoxia or hypoxia.

Judicious use of blood transfusions

Transfusion of packed RBCs is another risk factor of ROP. Adult RBCs are rich in 2,3 DPG and adult Hb binds less firmly to oxygen, thus releasing more oxygen to the retinal tissue. Packed cell transfusions should be given when hematocrit falls below following ranges:

- Ventilated infants: 40%
- Infants with cardio-pulmonary disease but not on ventilators: 35%
- Sick infants but no cardiopulmonary instability: 30%,
- Symptomatic anemia (tachycardia >180/minute or respiratory rate > 60 for 24 hour, doubling of the oxygen requirement in last 48 hours, lactate > 2.5 mEq/L or acute metabolic acidosis with pH <7.20 or weight gain less than 10 grams/kg/day over 4 days while receiving 120 kcal/kg/day): 25%
- Asymptomatic anemia: 20%.

Other interventions

Supplementation of high doses of Vitamin E or reduced ambient light exposure is not associated with reduced incidence of ROP.

In neonates with early stages of ROP administration of supplementation oxygen to achieve oxygen saturation in supra-physiological range and to reduce retinal hypoxia is not associated with halt in progression of ROP.

Quality improvement

Protocolized approach

- All units caring for babies at risk of ROP should have a written protocol in relation to the screening for, and treatment of, ROP. This should include responsibilities for follow-up of babies transferred or discharged from the unit before screening is complete.
- If babies are transferred either before ROP screening is initiated or when it has been started but not completed, it is the responsibility of the consultant neonatologist to ensure that the neonatal team in the receiving unit is aware of the need to start or continue ROP screening.
- Whenever possible ROP screening should be completed prior to discharge. There should be a record of all babies who require review and the arrangements for their follow-up.
- For babies discharged home before screening is complete, the first follow-up out-patient appointment must be made before hospital discharge and the importance of attendance explained to the parents.

Auditing

Following outcomes should be regularly audited in units with ROP screening and treatment program.

- Completeness of screening program: Percentage of eligible babies who receive at least one ROP eye examination
- Timing of first screen: Percentage of eligible babies receiving first ROP screening exam by 4 weeks of postnatal age.
- Timing of treatment: Percentage of babies needing ROP treatment for their ROP who are treated within 48 hours of the decision to treat being made.

References

1. Kumar P, Sankar MJ, Deorari A, Azad R, Chandra P, Agarwal R, et al. Risk factors for severe retinopathy of prematurity in preterm low birth weight neonates. *Indian J. Pediatr.* 2011;78:812-6.
2. Sivanandan S, Chandra P, Deorari AK, Agarwal R. Retinopathy of Prematurity: AIIMS, New Delhi Experience. *Indian Pediatr.* 2016;53Suppl2:S123-8.
3. Maheshwari R, Kumar H, Paul VK, Singh M, Deorari AK, Tiwari HK. Incidence and risk factors of retinopathy of prematurity in a tertiary care newborn unit in New Delhi. *Natl. Med. J. India.* 1996;9:211-4.
4. Narayan S, Aggarwal R, Upadhyay A, Deorari AK, Singh M, Paul VK. Survival and morbidity in extremely low birth weight (ELBW) infants. *Indian Pediatr.* 2003;40:130-5.
5. Charan R, Dogra MR, Gupta A, Narang A. The incidence of retinopathy of prematurity in a neonatal care unit. *Indian J. Ophthalmol.* 1995;43:123-6.
6. Dutta S, Narang S, Narang A, Dogra M, Gupta A. Risk factors of threshold retinopathy of prematurity. *Indian Pediatr.* 2004;41:665-71.
7. Vinekar A, Dogra MR, Sangtam T, Narang A, Gupta A. Retinopathy of prematurity in Asian Indian babies weighing greater than 1250 grams at birth: ten year data from a tertiary care center in a developing country. *Indian J. Ophthalmol.* 2007;55:331-6.
8. Rekha S, Battu RR. Retinopathy of prematurity: incidence and risk factors. *Indian Pediatr.* 1996;33:999-1003.
9. Gopal L, Sharma T, Ramachandran S, Shanmugasundaram R, Asha V. Retinopathy of prematurity: a study. *Indian J. Ophthalmol.* 1995;43:59-61.
10. International Committee for the Classification of Retinopathy of Prematurity. The International Classification of Retinopathy of Prematurity revisited. *Arch. Ophthalmol. Chic. Ill* 1960. 2005;123:991-9.
11. Azad R, Chandra P, Gangwe A, Kumar V. Lack of Screening Underlies Most Stage-5 Retinopathy of Prematurity among Cases Presenting to a Tertiary Eye Center in India. *Indian Pediatr.* 2016;53Suppl2:S103-6.
12. Fierson WM, Saunders RA, Good W, Palmer EA, Phelps D, Reynolds J, et al. Screening Examination of Premature Infants for Retinopathy of Prematurity. *Pediatrics.* 2013;131:189-95.
13. Sun X, Lemyre B, Barrowman N, O'Connor M. Pain management during eye examinations for retinopathy of prematurity in

- preterm infants: a systematic review. *Acta Paediatr. Oslo Nor.* 1992;2010;99:329-34.
14. Stevens B, Yamada J, Ohlsson A, Haliburton S, Shorkey A. Sucrose for analgesia in newborn infants undergoing painful procedures. *Cochrane Database Syst. Rev.* 2016;7:CD001069.
 15. Dempsey E, McCreery K. Local anaesthetic eye drops for prevention of pain in preterm infants undergoing screening for retinopathy of prematurity. *Cochrane Database Syst. Rev.* 2011;CD007645.
 16. Athikarisamy SE, Patole S, Lam GC, Dunstan C, Rao S. Screening for retinopathy of prematurity (ROP) using wide-angle digital retinal photography by non-ophthalmologists: a systematic review. *Br. J. Ophthalmol.* 2015;99:281-8.
 17. Good WV, Early Treatment for Retinopathy of Prematurity Cooperative Group. Final results of the Early Treatment for Retinopathy of Prematurity (ETROP) randomized trial. *Trans. Am. Ophthalmol. Soc.* 2004;102:233-248-250.
 18. Andersen CC, Phelps DL. Peripheral retinal ablation for threshold retinopathy of prematurity in preterm infants. *Cochrane Database Syst. Rev.* 2000;CD001693.
 19. Chawla D, Darlow BA. Anti-Vascular Endothelial Growth Factor Preparations in the Treatment of Retinopathy of Prematurity: Balancing Risks and Benefits. *Indian Pediatr.* 2016;53 Suppl 2:S129-36.
 20. Mintz-Hittner HA. Treatment of retinopathy of prematurity with vascular endothelial growth factor inhibitors. *Early Hum. Dev.* 2012;88:937-41.
 21. Good WV, Palmer EA. Bevacizumab for retinopathy of prematurity. *N. Engl. J. Med.* 2011;364:2359; author reply 2361-2362.
 22. Gilbert CE, Zin A, Darlow B. Bevacizumab for retinopathy of prematurity. *N. Engl. J. Med.* 2011;364:2359-2360.
 23. York JR, Landers S, Kirby RS, Arbogast PG, Penn JS. Arterial oxygen fluctuation and retinopathy of prematurity in very-low-birth-weight infants. *J. Perinatol. Off. J. Calif. Perinat. Assoc.* 2004;24:82-7.
 24. SUPPORT Study Group of the Eunice Kennedy Shriver NICHD Neonatal Research Network, Carlo WA, Finer NN, Walsh MC, Rich W, Gantz MG, et al. Target ranges of oxygen saturation in extremely preterm infants. *N. Engl. J. Med.* 2010;362:1959-69.