

Neonatal Chest X-ray interpretation

Dr Praveen Kumar, Additional Professor

Neonatal unit, Department of Pediatrics, PGIMER, Chandigarh

Learning Objectives

At the end of this session, you should be able to:

1. Schematically read and describe a neonatal chest X-ray
2. List and identify the typical radiologic features of common causes of respiratory distress in the newborn
3. Understand the variations and overlap in the radiologic picture of above disorders
4. Identify the complications of the disease and of mechanical ventilation

Indications for doing a CXR

1. For initial diagnosis of the cause of respiratory distress
2. To check the position of endotracheal tube, umbilical arterial and venous lines, and chest tubes
3. In case of respiratory deterioration which is not due to secretions, tube block or ventilator problems

Indications for NOT doing a CXR

Before ordering, think what you are expecting to find in the CXR and would that alter management.

- ▣ There is no need to do daily CXRs in ventilated babies.
- ▣ There is no need to do routine pre and post extubation CXR.
- ▣ There is no need to do CXR after each reintubation to confirm tube position. (Based on initial X-rays, identify the tube marking at lip which corresponds to correct placement. Note that down prominently on the bedside and insert tube to that mark.)
- ▣ There is no need to blindly order CXR everytime SpO₂ drops or oxygen needs go up. Examine the baby clinically and make a judgement as to what is the cause.

Schematic reading

Describe the following

- ▣ Quality of exposure
- ▣ Rotation

- ▣ Soft tissues
- ▣ Bones
- ▣ Lungs: Expansion
 - Cardiac and diaphragm margins
 - Parenchymal appearance - lucency, nature of opacities, fissure
- ▣ Cardiac: Size -CT ratio
 - Borders
 - Specific chamber enlargement

If the X-ray includes the knees as is often the case, an assessment of gestation may also be possible. Presence of endotracheal tube, central lines and minimal or no gas in the intestines indicate the sickness of the baby.

Normal CXR

Normal neonatal CXRs are all AP films taken in supine position. Lateral films can be useful to accurately localize the position of endotracheal tube, umbilical arterial and venous lines and also to diagnose pneumothorax. The chest is more cylindrical and translucent and ribs more horizontal compared to children and adults. Thymus is often prominent and normal CT ratio can be up to 0.6. Air bronchograms can be present till second generation of bronchi in the retrocardiac area. Diaphragm is normally upto 6th rib anteriorly and 8th rib posteriorly. Anything more than that would be hyperinflation and less would be underaeration. Residual lung fluid may give appearance of diffuse opacification during first 4 hours of life.

Evidences of hyperinflation

1. Lung expansion > 6 ribs anteriorly or 8 ribs posteriorly
2. Flattening of diaphragms
3. Increased lucency of lungs
4. Air under the heart or herniation of lung to other side
5. Ribs more horizontal

Correct endotracheal tube position

About 2 cm above the carina. Identify the carina by tracing the trachea downwards to its bifurcation

Correct umbilical arterial position

High: Between T6 and T9 thoracic vertebrae

Low: Between L3 and L4 vertebrae

Correct umbilical venous position

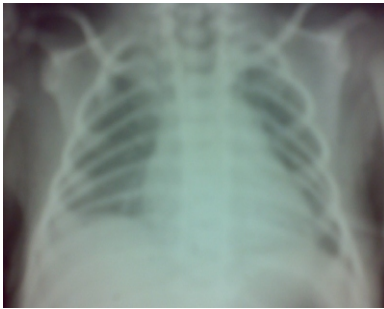
0.5 - 1 cm above the diaphragm (in IVC)

Correct percutaneous central venous line position

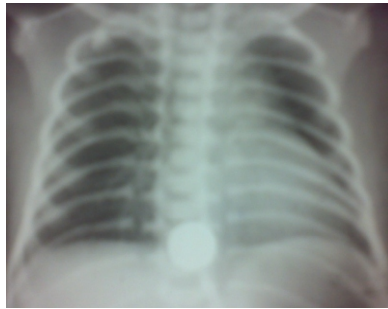Hyaline Membrane Disease (HMD)

Decreased lung volume
 Reticulogranular pattern
 Ground glass opacification
 Air bronchograms
 Whiteout lungs

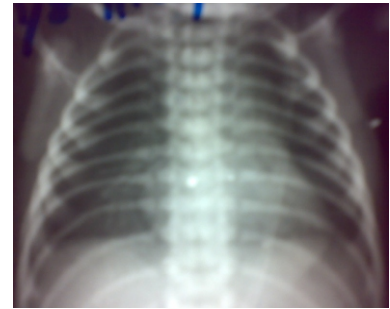
Note: The disease classically evolves over first few hours, so an X-ray done initially may not show all the changes. Changes can be occasionally asymmetric. Lung volumes may appear normal because of ventilation and surfactant administration may result in patchy areas of aerated lung interspersed with foci of residual atelectasis



Before CPAP application



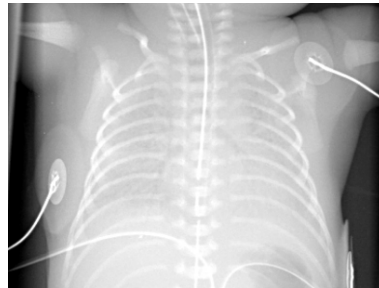
After CPAP application



Over-distension after CPAP application

Differential diagnosis of sudden white out X-ray in a baby recovering from HMD

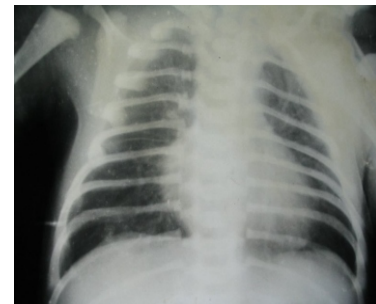
Pulmonary edema (PDA)
 Pulmonary hemorrhage
 Pneumonia



Rapid decrease in ventilatory settings causing underaeration (may also happen following endotracheal suction)

Transient tachypnoea of newborn (TTNB)

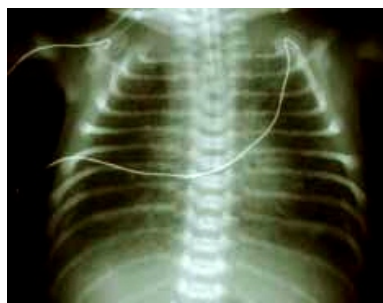Prominent hilum with streaky shadows
 Prominent interlobar fissures
 Small pleural effusion
 Mild cardiomegaly
 Normal to increased lung volume



MAS with Hyperinflation

Fluffy or nodular opacities

Air leaks

**Pneumonia**

Patchy alveolar or interstitial infiltrates

Consolidation

Usually normal to increased lung volumes with areas of air trapping

Pulmonary interstitial emphysema (PIE)

Tortuous tubular or ovoid translucencies emanating from hila and then extending peripherally in a perivascular distribution

Honey comb appearance

Subpleural blebs

Pneumothorax

Pleural air with no or decreased lung markings (hyperlucent)

Collapsed lung

Shift of mediastinum to opposite side

Note: Since babies are lying supine, and the lungs are stiff preventing collapse, air may collect anteriomedially. As a result, lung markings may still be seen. Even though air volume may appear small, it is enough to cause 'tension' and all pneumothoraces in a ventilated baby should usually be considered as ' tension pneumothorax'.

To differentiate from 'skin fold', trace the outline of the lucency; if it crosses diaphragm or upwards into the neck, it is a skin fold.

Pneumomediastinum

Medial air adjacent to heart outlining the mediastinum and elevating thymus away from heart (In pneumothorax, thymus is compressed against heart)

Retrosternal air on lateral film

Pneumopericardium

Air all around the heart

Chronic lung disease (CLD)

Northway 1967

Stage I : Changes of HMD

Stage II : Increasing opacification

Stage III : Cystic translucencies (oval or spherical) of varying size

Stage IV : Coarse linear densities
Irregular emphysematous cysts
Increased lung volume

Nowadays, most common appearance of CLD is that of diffuse interstitial thickening with mild to moderate hyperinflation

Diaphragmatic hernia

Usually left hemithorax filled with cyst like loops of bowel

Mediastinal shift to opposite side

Pitfalls and Practical Tips

While doing the X-ray

- ☐ Asepsis precautions: Wash hands (including radiographer)
X-ray plate - avoid direct contact with baby(use X-ray tray provided with the open care system), cover with sterile plastic sheet/envelope
- ☐ Prevent hypothermia: Avoid direct contact with the cold X-ray plate
Provide extra heat source as the open care heater is moved away from the baby or tilt its direction towards baby if possible
For babies in incubator, X-ray can be done through the incubator only
- ☐ Radiation : Lead apron for the nurse/resident and gonad shield for the baby
- ☐ Don't forget the Left and Right marking
- ✂ Ask the radiographer to note down the exposure settings - this will help in determining the optimal exposure for the baby.
- ☐ Expose only the area of interest
- ☐ Remove unnecessary things from the chest and move aside monitor leads, tubing's etc. Avoid putting big plasters/sticking on the chest
- ☐ Make sure baby is not rotated at neck or spine
- ☐ Make sure baby's back is in full contact with the bed/plate in all areas to avoid air pockets between skin and plate
- ☐ Quieten the baby to avoid swings in respiratory depth

While reading the X-ray

- ☐ Read schematically, Do not jump to the diagnosis - you will miss important additional findings
Make differential diagnosis and correlate clinically
Write age in hours/days on the X-ray.

- ▣ If a baby is having multiple X-rays, it is helpful to write the serial numbers on the films
- ▣ Mark on the X-ray if ET tube or central lines have been moved
- ▣ A magnifying glass and focused light source is often useful.
- ▣ Learn to read yourself; do not rely on routine pediatric radiologist if he/she has not been reading neonatal films regularly.